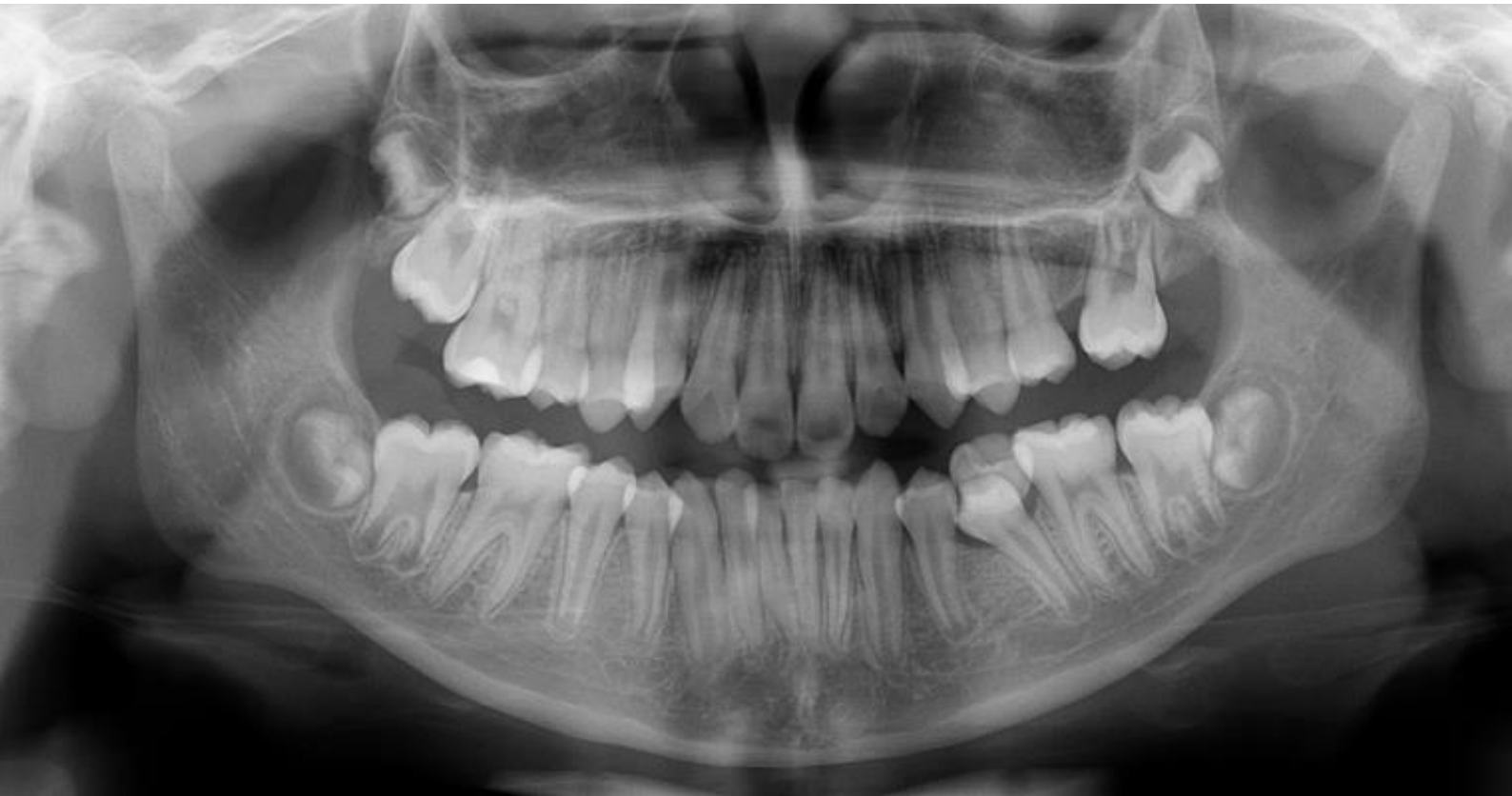

Practical Guide to Dental Radiology

First Edition





Acknowledgments

The Australian Dental Association wishes to express its gratitude to the authors for their efforts in the creation of these guidelines.

Clinical Professor Bernard Koong, BSc (W.Aust), MSc (OMR)(Toronto), FICD, FADI,
FPFA Oral and Maxillofacial Radiologist.

Dr May Lam, BSc (Hons)(W.Aust), FRACDS (GDP)
Oral and Maxillofacial Radiology Registrar (Qld)

Dr Tom Huang, BSc (Hons1)(Qld), DClinDent(DMFR)(Qld)
Oral and Maxillofacial Radiologist

Practical Guide to Dental Radiology
First Edition 2019

Published by the Australian Dental Association, PO Box 520, St Leonards, NSW 1590, Australia
© Australian Dental Association 2019

All rights are reserved. No part of this work may be reproduced or copied in any form or by any means, electronic or mechanical, including photocopying, without the written permission of the publisher, the Australian Dental Association

Foreword

This *Practical Guide to Dental Radiology* is a significant addition to the ADA's series of *Practical Guides to Dental Equipment and Materials*, which provide hands-on information specific to practice in the dental sector.

Radiation technology is an important diagnostic tool in dentistry, hence the need to develop an up-to-date guide on the available technologies, their use in prescription, their interpretation, their types and application.

While radiation regulation currently varies by state and there is guidance available at the state and national levels through the various Government Agencies, an overall view of radiology has been missing and this inaugural edition has been developed to provide a succinct summary of the key aspects of practical radiology as they relate to dentistry.

Optimal imaging, quality control and interpretation of images is essential in achieving the maximum diagnostic capability in all dental radiology. This guide is developed with this in mind, and it is hoped that it will be useful to enhance the understanding of radiation technologies (and how they apply in the surgery) of all staff working in the clinical area of the dental sector.

Safety is also paramount and dental radiology should only be prescribed and performed by appropriately trained and qualified dental and medical professionals (and in some states licencing is required). While safety in radiology is not the main focus of this document, it does address the important issue of how to minimise the risks of radiation exposure to both patients and to staff alike. To do this effectively requires an understanding of the advantages and disadvantages of the diagnostic benefits of dental radiology.

The ADA gratefully acknowledges the scientific expertise of Clinical Professor Bernard Koong, Dr May Lam and Dr Tom Huang, who volunteered their time in developing this comprehensive evidence-based practical guide. The ADA also acknowledges the ongoing contributions of the volunteers on the ADA Dental Instruments, Materials and Equipment Committee, who were also involved in the creation of this guide.

Further information regarding regulation, codes and standards of radiology in Australia is available by consulting the relevant government agency in your state and at the national level, the Australian Radiation Protection and Nuclear Safety Agency (ARPANSA). You may also like to refer to the ADA's Policy 6.14 Radiation Safety.

I hope you find this practical guide a valuable resource.

Dr Carmelo Bonanno
Federal President



Contents

Foreword	3
Introduction	5
Chapter 1: Intraoral radiology – a review	6
Chapter 2: Panoramic radiographs – a review	10
Chapter 3: Multi-detector CT and cone beam CT	13
Chapter 4: Other advanced techniques: MRI, ultrasound and nuclear medicine	17
Chapter 5: Prescription and radiologic interpretation	19



Introduction

This radiology practical guide is constructed around a series of evidence-based articles on contemporary radiology in dentistry by Clinical Professor Bernard Koon and Drs May Lam and Tom Huang.

Continued advances in radiology have substantially contributed to diagnosis and management. Clinicians are continually challenged to be familiar with all available modalities in order to prescribe the optimal radiological test for their patients.

The first four chapters discuss the various modalities, including intraoral radiography, cone beam computed tomography, multislice computed tomography and MRI. The final chapter aims to assist the clinician in the prescription of the appropriate test for the common conditions encountered in practice.

Chapter 1: Intraoral radiography - a review

This chapter focuses on intraoral 2D radiography, namely periapical and bitewing radiographs. The table below compares intraoral radiography technology based upon the type of detector.

Technology

	Film radiography	Direct capture radiography	Indirect capture radiography
		CCD (charged coupled device) CMOS (complementary metal oxide semi-conductor).	PSP (photostimulable phosphor) plates.
Method of image capture	Exposure to an X-ray beam results in a latent image recorded on the emulsion-coated film. Chemical processing generates the radiographic image	The X-ray beam causes silicon crystals in the sensor to convert photons to electrons. The signal is transmitted to the computer which depicts a real time image.	The surface of the PSP is ionised upon X-ray exposure. When the plate is fed into a scanner, the latent image is transmitted to the computer which depicts the image.
Ease of use		Positioning is often more difficult and uncomfortable due to sensor bulk and rigidity of the cable.	Resembles film radiography and better tolerated by patients.
Radiation dose levels	Effective dose commonly ranges from 5–9 μSv , although 0.1–9 μSv have been reported.	Reduced radiation dose due to increased sensitivity of sensor compared to film. With optimal settings, the potential for dose reductions of up to 40–60% have been reported.	Depending on exposure settings, PSP radiation dose is less than film, but more than direct capture radiography.
Risk of overexposure	Dark film will alert the operator to overexposure.	Blooming artefacts (i.e. the pixels are 'burnt out' and appear black) will alert the operator to overexposure.	A useable image will still be produced at high radiation doses. As a result, overexposure and increased patient radiation dose may occur without operator awareness.
Frequency of retakes and errors	Chemical processing of film is technique sensitive, potentially contributing to retakes.	Higher number of retakes (up to 28%) have been quoted due to a smaller active capture area and difficulty in positioning of a thick and rigid sensor.	The larger dynamic range of PSP may decrease retakes, but the potential of unrecognised overexposure must be considered. Latent image quality may be lost due to the spontaneous release of electrons, or exposure to ambient lighting. PSP plates should be scanned no later than 10 minutes after exposure. Erased plates must be kept in light-tight containers.
Image resolution (measured in linepairs per mm lp/mm)	≥ 20 lp/mm	7–15 lp/mm Theoretically may achieve ≥ 20 lp/mm, but this is not often possible in practice.	5–13 lp/mm has been quoted. Lower than film and direct digital radiography. Visibility of small endodontic file tips are potentially suboptimal.
Cost	Comparatively low cost	High initial system cost is more durable than PSP, but physical damage can occur.	Regular replacement of PSP is necessary. The lifespans of a PSP have been quoted between 50–200 uses. Damage to the phosphor layer (e.g. scratches, folds) may render the PSP non-useable.
Other advantages		Ease of digital storage and transmission of image. No need for darkroom equipment	
Other disadvantages	Associated hazardous waste and lead foil from film processing.	<ul style="list-style-type: none"> Ease of use may potentially increase the number of exposures. Infection control may be a problem as the detectors cannot be sterilised. Wiping with an alcohol-impregnated tissue has been suggested, but it is uncertain to what degree the sensors tolerate wiping. 	

REDUCING RADIATION EXPOSURE

The following summarises some of the ways in which dose minimisation can be achieved:

- Adopt the principle of ALARA (as low as reasonably achievable).
- Review relevant previous studies prior to further imaging. Request from previous clinician if necessary.
- Use the fastest image receptor compatible with the diagnostic task (F-speed film or digital).
- Benefits associated with the use of lead aprons have been shown to be minimal compared to other methods of dose reduction. As such, this could be considered optional unless required by relevant governing bodies.
- Thyroid shields have been shown to reduce thyroid radiation dose.
- Rectangular collimation has been suggested, substantially reducing dose. However, it is technically more demanding, and its use must be balanced against the possibility of repeats, potentially increasing the overall dose delivered.
- Use a film positioning device to aid in the parallel alignment of the film with the collimated beam to minimise geometric distortion and for reproducibility of subsequent radiographs.
- Use optimal settings to minimise exposure times.
- Minimise the number of images necessary to obtain essential diagnostic information.
- Optimal film exposure and processing technique.
- Implement quality assurance protocols to regularly evaluate the film processor, image receptor devices and processing chemistry.

The justification and selection criteria for intraoral radiographic examination have been thoroughly outlined by various bodies, including the American Dental Association and the European Commission. A radiologic examination should be undertaken only when it provides additional information about a condition or planned procedure and/or influences management or surgical approach. Other factors, including the patient's history and susceptibility to dental diseases should also be considered. The benefit must outweigh the accumulated biological risk to the patient.

The clinician needs to prescribe the optimal technique based on clinical indications. The practise of initially prescribing conventional examinations (e.g. plain film 2D radiographs) before determining whether 3D volumetric information is needed has been suggested. However, the limitations of 2D imaging (geometric distortion and projection errors, overlapping of anatomical structures and image magnification) have been well documented and may lead to difficulty with diagnosis and misinterpretation of results. In situations where 2D radiography is neither sufficiently sensitive nor specific, or multiple exposures are required to visualise an area, more advanced techniques should be considered.

In the following subsections, brief references to cone-beam computed tomography (CBCT) and multi detector computed tomography (MDCT) are made where relevant. Chapter 3 addresses volumetric techniques in more detail.

APPLICATION

Bitewing radiographs

The bitewing (BW) radiograph remains the most optimal technique for detecting interproximal caries but may not be necessary in patients who show no evidence of the disease, have open proximal contacts or a low caries risk. Diagnosis should be made in conjunction with a clinical examination as low sensitivity (0.24–0.42) and high specificity (0.70–0.97) have been reported. The frequency of their prescription should be determined based on caries risk assessment and altered as the individual circumstances of the patient changes with time.

Several studies have reported that CBCT may be useful for caries detection but is not recommended as the primary technique for caries diagnosis on account of the potential for higher radiation dose, low specificity and beam hardening artefacts when metallic or radiodense restorations are present.

Furcation defects and the more superficial periodontal bone can be demonstrated in a BW, which is taken at right angles to the X-ray beam.

Periapical radiographs

For periodontal disease, the periapical (PA) radiograph demonstrates a 2D view of periodontal bone and root morphology, with associated limitations. Foreshortening or elongation of the teeth occur, resulting in distortion and inaccurate assessment of the true horizontal bone height.

Image distortion is worse when using a bisecting angle technique. Limited sensitivity for measuring the degree of periodontal bone loss, mapping infrabony and vertical defects and the assessment of furcation involvements have been reported. The existence and severity of bone loss demonstrated in one imaging episode does not indicate active disease. Therefore, radiological examinations should be correlated with clinical findings, and compared with previous imaging where relevant. Increasingly, for more complex cases, the use of volumetric (3D) imaging has been suggested to allow for more accurate detection, diagnosis, prognosis prediction and treatment planning.

For periapical disease, a PA radiograph correlated with clinical findings is generally sufficient for most cases. However, the limitations of these 2D views must be recognised. It has been shown that MDCT and CBCT are more sensitive for the detection of periapical lesions.

For the initial diagnostic stages of implant planning, PA radiographs may be helpful as a preliminary guide on bone availability and proximity to anatomical structures. However, PA radiographs are insufficiently accurate for the final planning for implant placement. The 3D morphology and relationship to relevant structures is not demonstrated. In this regard, volumetric imaging techniques are superior and generally accepted as the modalities of choice.

PA radiographs have been recommended for the measurement of baseline bone levels after implant placement. It is obvious that 2D radiographs only demonstrate the proximal peri-implant bone and optimal paralleling technique is essential. CBCT and MDCT may be useful in some cases, but are not without their limitations, namely the adjacent artefact.

For most cases of dental trauma, at least two PA radiographs with different horizontal and vertical angulations have been recommended. They may be sufficiently accurate for minor dental injuries, but low sensitivity in detecting fractures have been reported. CBCT and MDCT may not be essential for acute management of minor dento-alveolar trauma. These techniques, usually low-dose protocol CBCT, should be considered where 2D radiography is inconclusive. Volumetric imaging could also be considered in the long-term management of trauma cases.

Other situations requiring volumetric imaging include cases with unresolved symptoms and more serious trauma, especially where injuries extend beyond the dento-alveolar complex. MDCT is the modality of choice over CBCT for more complex cases.

The information provided by a PA radiograph may be insufficient for surgical and/or orthodontic treatment planning for impacted canines and their relationship to adjacent structures. Ultra-low dose CBCT is emerging as a modality of choice, as it is able to demonstrate the precise location and morphology of the tooth, the surrounding structures and detection of root resorption of adjacent teeth.

Overall, there are increasingly fewer indications for vertex occlusal views as well as the full mouth series with the advent of CBCT. Volumetric imaging is discussed in Chapter 3.

VIEWING CONDITIONS

To ensure the highest diagnostic accuracy, it is important to review radiographs under optimal conditions. Low ambient lighting (no more than 50 lux), a bright backlight source and magnification is recommended for film radiographs. Use of a mask to reduce glare from light boxes around the film is also helpful. With more steps involved in digital image acquisition and display, any component in this process can influence the quality of the final image.

Display monitor:

With advances in commercial display monitor technology, these monitors (with correct specifications – see below) are comparable with medical grade monitors for most diagnostic purposes.

Maximum brightness High luminance profile of $\geq 300 \text{ cd/m}^2$ (room brightness reduces the contrast ratio and making small contrast differences more difficult to observe)

Calibration Compliance to DICOM Part 14 GSDF standards

Screen properties Size: 20 inches recommended; ranges of 17-24" have been quoted
Finish: matt finish to minimise the reflection of ambient lighting

Resolution Ideally, 2048 x 1536 pixels (3 megapixels), but at least 1920 x 1080 (2MP) is indicated. If incorrect display resolution is chosen, geometric distortion or excessive magnification can result.

Contrast ratio $\geq 500:1$

Response time Around 8 milliseconds

Greyscale bit- depth ≥ 8 -bit greyscale (24-bit or 32-bit colour)

Video display interface Digital (e.g. DVI, displayport)

Graphics card:

- Should be appropriately matched and of high quality to avoid information loss and inferior quality images.

Image enhancements and manipulation:

- Zoom control may aid in radiologic diagnosis of proximal carious lesions. It has been suggested that the optimum magnification should be no more than six times the original.
- Enhancement of density and contrast may improve diagnostic accuracy.

- Inverting greyscale values has not been found to improve diagnostic accuracy. Instead, it may hinder dental lesion detectability.
- Pseudo-colour enhancement has not been documented to aid diagnosis.

Storage and transmission:

- The image should be stored in its original, uncompressed format with an automatic backup function. Minimising compression of the radiographic image during transmission is necessary to avoid loss of relevant data.

Printed copies of radiographs compromise diagnostic accuracy and are not recommended. They are highly dependent on the quality of printer and paper and will not demonstrate the same optical range as film or high-quality monitors.

INTERPRETATION

The importance of applying a methodical approach to radiological interpretation is critical.

Radiological interpretation is discussed in Chapter 5.

Chapter 2: Panoramic radiographs – a review

TECHNOLOGY

Film, direct and indirect digital image receptors are used in panoramic radiography, with digital receptors becoming increasingly popular. There are a few differences with regards to the film and detector technology in relation to those employed in intraoral radiography (Chapter 1):

- **Film systems:** an intensifying screen with rare earth elements is used to minimise radiation exposure to the patient. A dose reduction of 50-55% has been quoted in the literature. This is achieved because film is also sensitive to the fluorescent light emitted from the intensifying screen. This light will either be of a blue or green wavelength and the appropriate film must be matched to the screen. Screen film combinations with a speed of 400 or greater are recommended.
- **Direct digital systems:** due to the expense of large detectors, three to four CCD sensors are arranged vertically to cover the height of the panoramic X-ray beam, and the image is constructed in increments.
- **Indirect digital systems:** storage phosphor plates of appropriate size replace screen films in traditional cassettes.

The radiation dose levels between the three systems are comparable. Although, direct digital radiography can produce lower doses than film and storage phosphor systems, if the lowest possible setting appropriate to the patient is chosen. The effective dose has been quoted at a range of 3.85–30 μ Sv. However, much higher doses have been reported with older film systems. If the patient is a child or of a smaller stature, protocols should be appropriately adjusted to reduce the radiation dose delivered.

TECHNICAL ASPECTS AND LIMITATIONS

The panoramic radiograph is produced by using the principles of conventional tomography. It is a simple curvilinear form of tomography where the X-ray source and the image receptor simultaneously rotate around the patient's head, capturing the structures within the focal trough. Structures outside of this zone are significantly distorted, blurred or magnified to the point where they are not recognisable, ideally leaving only the dentition and adjacent structures in clearest view possible.

In addition to the usual disadvantages associated with 2D imaging (geometric distortion and projection errors, overlapping of anatomical structures, image magnification and lack of 3D information), there are additional limitations unique to panoramic imaging, detailed in most radiology texts. Some are listed below:

- Lower resolution compared with intraoral radiography and computed tomography (CT).
- Clinically relevant features may be missed if outside the focal trough.
- Real, double and ghost images are always present and familiarity with their appearances is important in the evaluation of anatomical structures and pathoses.
- Overlapping of the proximal surfaces of teeth is common, usually the premolars.
- Superimposition of the cervical spine over the incisor region is usually present.
- Unequal magnification and distortion is found throughout the image, making linear measurements unreliable. Horizontal magnification is much more unpredictable than vertical magnification.
- Objects located more lingually will be projected superiorly due to the slight craniocaudal orientation of the beam.

The technical aspects are well covered in many texts. Incorrect positioning on the bite-block, and/or rotation of the patient's head are two of the most common positioning errors which can lead to significant geometric distortion and horizontal magnification/minification of the image.

- Magnification of the teeth occur when the jaw has been lingually positioned in relation to the focal trough, and is therefore closer to the X-ray source, causing the beam to pass through it more slowly. Conversely, objects more buccally placed will appear narrower.
- One method to assist in the identification of horizontal distortion is comparing the width of the mandibular first molars. The smaller side was positioned too close to the receptor, while the larger side would have been too close to the X-ray source.
- If the chin is tilted excessively high (chin up), the mandible will be distorted with a flat or inverted occlusal plane, and the hard palate will be superimposed on the roots of the maxillary teeth. Conversely, if the chin is too low (chin down), both the condyles and symphyseal region of the mandible will not be captured and there will be excessive overlapping of the dentition.

REDUCING RADIATION EXPOSURE

Similar principles to intraoral radiography apply. This was discussed in Chapter 1.

APPLICATION

For a relatively low radiation dose, the panoramic radiograph remains a useful overview of the dentoalveolar and surrounding structures. However, a lack of understanding of the substantial limitations can contribute to misdiagnosis. On the other hand, even with these limitations in mind, it can be sufficient for many situations and procedures. Where clinically appropriate, it may be a useful initial test, where relevant further imaging could then be considered. It may also be useful for patients who cannot tolerate intraoral radiography, but it is not a substitute for the information that can be obtained from an intraoral radiograph.

Panoramic radiographic imaging is reported to be inadequate for the diagnosis of dental caries. The intraoral bitewing radiograph remains the imaging of choice. Some panoramic machines offer an 'extraoral bitewing radiograph', suggested to help with patients who are unable to tolerate intraoral radiography. Reduced specificity due to ghost artefacts, superimposition of air spaces and overlapping of premolars has been reported. Extraoral bitewing radiographs have been shown to be inferior to intraoral radiographs.

Also, the panoramic radiograph is not the optimal technique for most other common dentoalveolar diseases. Compared to intraoral radiographs, it is less sensitive in its ability to detect periapical lesions, particularly those exhibiting early periapical changes. As well, it often underestimates the extent of periodontal osseous defects. Findings on a panoramic radiograph may need to be supplemented with intraoral radiographs or 3D imaging as appropriate.

The panoramic radiograph has been considered to be appropriate for most cases of tooth extraction, including removal of third molars. Volumetric imaging should be considered for more complicated or difficult cases, and where plain film appearances suggest that the tooth is in close proximity to critical structures, such as the mandibular canal.

It has been suggested that panoramic imaging could be used for the initial radiologic assessment in evaluation for the dental implant, supplemented by 3D imaging techniques.

Given its low radiation dose, low cost and easy accessibility, some authors suggest that panoramic imaging can be used for pre-implant vertical linear measurements in the posterior mandibular region by calculation with the appropriate magnification factor and allowing a 2 mm safety margin superior to the inferior alveolar canal or other significant anatomical structures. However, the degree of magnification and minification is unpredictable, and other important 3D variables such as the prominence of the submandibular fossa or the precise morphology and proximity of the maxillary sinus floor cannot be appreciated in these 2D views.


It has been suggested that without 3D imaging, a safety margin of 6 mm from the mental foramen would be required, which may contribute to suboptimal treatment planning. There are many factors which influence the accuracy of this method, such as incorrect patient positioning, distortion, discrepancies between the shape of the dental arch and focal trough, and beam angulation. It has been reported that only 17% of measurements from the alveolar crest to the inferior alveolar canal have errors within one millimetre. Panoramic imaging is inferior to volumetric imaging for visualisation of many critical anatomical structures. In general, pre-implant volumetric imaging is considered essential.

The panoramic radiograph is considered to be particularly useful in the evaluation of the developing dentition and any anomalies. However, it is important to remember that supernumerary teeth or pathologies are likely to be missed if not located within the focal trough.

For the assessment of impacted and/or ectopic canines, panoramic radiography alone is considered to be inadequate due to its limitations including the inability to provide 3D information on the buccal or palatal position of the tooth. Cone beam computed tomography better demonstrates the relationship of the impacted canines and adjacent structures, root position and morphology, and possible associated root resorption. The use of volumetric imaging in treatment planning is considered to improve outcomes. Ultra-low dose CBCT protocols are recommended for the younger patient.

Even though the temporomandibular joints (TMJ) are seen in most panoramic radiographs, it is considered to be an insufficient test where there are specific indications for a radiologic examination of these joints. These views are unable to depict the precise morphology of these joints. The typically oblique projection of these joints together with variations in condylar angulation contribute to a distorted image. Without the ability to view the articular surface, pathologies such as erosions and osteophytes in the TMJ are detected with low sensitivity. CT and magnetic resonance imaging are the optimal techniques for the bony and soft tissue structures of the TMJ respectively. These techniques are discussed in Chapter 3. However, the TMJs are almost always depicted in the panoramic radiograph and, despite the limitations, their appearances should be thoroughly evaluated.

Panoramic imaging is inadequate and unreliable for visualisation of sinus anatomy. There is often misinterpretation of the proximity of the maxillary tooth roots to the sinus due to the 2D nature of the image and the presence of distortion. In situations where 3D information is necessary for accurate and precise planning (such as in sinus grafting procedures, or evaluating the likelihood of an oroantral communication), volumetric imaging is recommended. Sinus disease cannot be fully excluded with the panoramic radiograph. However, the sinuses are demonstrated in these views and due attention should be made as significant disease is sometimes demonstrated.



Although routine panoramic radiographic screening for extra-gnathic occult diseases cannot be recommended, the operator should be aware of these additional findings, including the clinical relevance. For instance, panoramic imaging has a low sensitivity for detecting calcified atheromas in the carotid artery or mandibular cortical erosion in the case of osteoporosis, but the presence of these findings contribute to the diagnosis and management of such conditions. Routine panoramic imaging of the patient at set arbitrary intervals is not considered to be justified.

VIEWING CONDITIONS

The viewing conditions in relation to panoramic imaging are similar to that of intraoral radiographs (Chapter 1).

INTERPRETATION

The relatively broad coverage and tomographic nature of the panoramic radiograph contributes to challenges in interpretation. It has been reported that dental students and dentists face challenges in identifying the radiologic anatomy, positioning errors and pathologies/anomalies relating to panoramic images. This highlights the need for advanced and continued education in the interpretation of these radiographs. The prerequisites include a thorough understanding of the limitations, the radiologic anatomy, orofacial pathology and radiologic features of pathoses. It is obvious that a systematic approach must be taken. All structures included in these radiographs must be appropriately evaluated. The practitioner presiding over the study is responsible for the thorough interpretation of the entire image, not only the region of interest. Radiologic interpretation is discussed in Chapter 5.

Chapter 3: Multi-detector CT and cone beam CT

This chapter focuses on volumetric (3D) imaging; multi-detector and cone beam computed tomography (MDCT and CBCT respectively).

The following table compares MDCT and CBCT technology.

THE TECHNOLOGY

	MDCT	CBCT
Method of capture	Thinly collimated, fan shaped X-ray beams rotate in a helical fashion around the patient to capture multiple image slices. A second collimator reduces the scattered photons before it contacts the multiple rows of detectors to improve image quality. The signal is then relayed to the computer for analysis and image construction.	A divergent cone or pyramidal shaped X-ray beam is directed through the region of interest to an area detector on the opposite side of the rotating gantry. Multiple sequential projections are performed as the platform moves through a single arc of 180 or 360 degrees. The multiple images obtained are computed to generate the final 3D volumetric data.
Detector type	Solid state detectors	Flat panel detector or image intensifier/CCD sensor
Patient positioning	Supine	Standing, sitting or supine
Image reconstruction	A back projection algorithm (most commonly the Feldkamp algorithm) is applied to reconstruct the volumetric images with a computer.	
Radiation dose levels	In imaging of the jaws, effective dose ranges of 280-1,410 μSv have been quoted. While there is variation between different types of scanners, imaging protocols substantially alter the doses delivered. Anecdotally, doses lower than those reported in the literature can be achieved.	Reported range of 5-1,073 μSv . Not all CBCT scans deliver low radiation doses. It is highly dependent on the type of unit and the protocols employed.
	The difficulty in making comparisons between CBCT units and between the different imaging modalities has been documented. A smaller field of view (FOV) in one unit may not necessarily deliver less radiation than a larger FOV in another unit. While ultra-low dose CBCT units, with appropriate low dose protocols, can deliver doses comparable to some panoramic radiographs, other types of CBCT units may deliver doses greater than a well optimised low-dose MDCT.	
Scan times	Substantially faster than CBCT in the imaging of orofacial structures.	Scan times are generally substantially longer than MDCT, with a typical range of 10-40 seconds. Scan times can be shorter for low resolution scans.
Spatial resolution	Sub-millimeter imaging (as small as 0.5 mm) is possible to generate high-spatial resolution images.	Usually higher spatial resolution than MDCT due to smaller voxel sizes, with a reported range of 0.076-0.4 mm. However, image resolution and quality range widely (refer to 'Disadvantages' below), potentially lower than MDCT.

TECHNICAL ASPECTS

MDCT machine operation should only be undertaken by an appropriately trained radiographer/radiologist.

The technical aspects of CBCT has been covered in various texts. Adequate training is essential, including a thorough understanding on the influence of protocols on image quality and radiation safety. The basic principles of reducing radiation exposure were discussed in Chapter 1. The following highlight some of the key issues in relation to CBCT:

- **Field of view:**
 - Selecting the smallest FOV for the region of interest (ROI) will improve the image quality and potentially significantly reduce radiation dose.
 - Large volume CBCT generally produce moderate resolution scans which may not be sufficient for fine detailed tasks such as examining nondisplaced tooth fractures or small root canals. High resolution small FOV CBCT may be more appropriate in such cases. Higher resolution scans are generally associated with higher radiation doses.
 - The FOV is limited by the size of the detector. Some units are capable of scanning a ROI which is larger than the FOV of the machine by stitching multiple scans together. However, this will result in an increased radiation dose and acquisition time. One scan with an appropriate larger FOV machine is therefore generally recommended over stitching of multiple scans.
- **Voxel size:** Smaller voxel sizes capture less X-ray photons, which results in images with more noise. Most CBCT units compensate for this by increasing the radiation dose.
- **Frame rate:** The more basis projection images captured, the more data available for reconstruction. This improves spatial and contrast resolution, decreases noise and reduces metallic artefacts. However, it increases patient dose, and also increases scan times with associated potential for motion artefact.
- **Trajectory arc:** Reduction in the rotation arc from 360 to 180 degrees will reduce the radiation dose by 50%. However, this will have a corresponding decrease in image quality.
- **X-ray generation:** Using a pulsed X-ray beam to coincide with detector sampling will reduce patient exposure by up to 50%.

ADVANTAGES

3D volumetric imaging overcomes the limitations of 2D imaging (superimposition, geometric distortion and magnification). The data from a single scan can be reformatted to be viewed along the axial, coronal, sagittal or any other plane (multiplanar reformatted images). Surface rendering facilitates viewing of the data as 3D virtual 'models'.

Compared with 2D plain films, CBCT and MDCT have both been found to be more accurate in measurements in any dimension. Several studies have found CBCT and MDCT linear measurements (over lengths comparable to a tooth) to be accurate within 1mm.

CBCT potential advantages:

- Easier accessibility, usually lower cost and smaller physical footprint than MDCT.
- Potentially lower radiation dose than MDCT. It must be noted CBCT scans can deliver relatively large radiation dose levels, potentially higher than a low dose MDCT scan (refer to 'The technology' on page 13).
- High osseous/calcified structure spatial resolution due to smaller voxel size, which can better depict bony trabeculae, root structure etc.

MDCT potential advantages:

- A more powerful and flexible imaging modality.
- Visualisation of soft tissues and scans with or without intravenous contrast may be critical in some cases.
- High contrast resolution, such that tissues with even 1% difference in physical density can be identified.
- Improved image quality due to better signal-to-noise ratio.

DISADVANTAGES

CBCT is subject to more detrimental effects on image quality than MDCT:

- Increased noise compared to MDCT:
 - A result of Compton scattering. The amount of scattered radiation is proportional to the volume of tissues in the X-ray beam, and can be reduced by decreasing the FOV.
- Poor soft tissue contrast:
 - The contrast resolution is limited to bony or calcified structures. CBCT has less overall contrast resolution than MDCT.
- Beam hardening:
 - Preferential absorption of lower energy photons through dense objects results in distortion of

objects, appearance of bands or streaks (extinction or missing value artefacts) which can contribute to misinterpretation of the scan. The size of the patient's head as well as the density of the object also contribute to the degree of beam hardening.

- Motion artefacts:
 - Occurs if the patient is unable to keep still for the entire scan time. This is a common problem as CBCT scan times are generally substantially longer than with MDCT. Selection of a shorter scan time may reduce this, but a decrease in scan time reduces image quality.
- Metal streaking artefacts:
 - The absorption of nearly the entire X-ray beam energy by metallic structures results in an opaque streak. This may obscure key structures.
- Cone-beam effect:
 - The peripheries of the image are subject to more image distortion, streaking artefacts and greater noise.
- Moire artefact:
 - Too few basis projection images occur resulting in undersampling of the object.
- Scanner related artefacts:
 - Appears as a circular streak, often due to poor calibration or imperfections in scanner detection.
- Inaccurate bone density estimation:
 - The grey values in CBCT cannot be quantified as Hounsfield units (HU), which measure the relative density of body tissues based on a calibrated grey-level scale. This is possible with MDCT.

The main limitations of MDCT are the potential for higher radiation doses, and reduced accessibility. In some cases, the MDCT image quality of teeth and osseous structures is comparable or better than CBCT scans. However, high resolution small FOV CBCT scans for persons who are not particularly large (with no motion artefact) produce higher quality images of the jaws and teeth than MDCT scans.

APPLICATION

In general, the prescription of 3D imaging should only be carried out in cases where lower dose imaging techniques are not able to provide the information required for diagnosis and treatment planning. Without specific indications, 3D imaging for routine screening is not recommended.

In recent years, there has been an increase in the use of CBCT in dentistry, primarily related to improved understanding of the application, accessibility and dose considerations. While a few authors consider that it has largely replaced MDCT for dentistry, the limitations of CBCT require consideration and it is not the optimal modality for many cases. Understanding of the strengths and limitations of both CBCT and MDCT is necessary for selection of the most appropriate radiologic test. In some instances, other modalities such as MRI, ultrasound or nuclear medicine may be optimal.

The indications for a CBCT/MDCT image has been outlined by various bodies. These position statements and guidelines will alter as the research in this field continues. The prescription of volumetric imaging, in relation to intraoral radiography (IOR) and OPG has been discussed in preceding chapters. The following discusses the more common application of CBCT and MDCT in dentistry:

- Despite its increased sensitivity for the detection of dental caries, CBCT has low specificity and is associated with a higher radiation dose than bitewing radiography. As such, it is not recommended as the primary imaging technique for dental caries. Also, metallic artefacts and beam hardening from adjacent restorations render CBCT inadequate for caries detection.
- MDCT and CBCT are more accurate than IORs and OPGs at identifying the severity of periodontal bone loss and infrabony defects, detecting furcation involvements and providing information on root morphology. With the associated contribution to diagnosis and prognosis, it has been suggested that treatment time and cost may be reduced with the better ability to make appropriate treatment decisions on whether to extract or maintain periodontally compromised teeth. However, it remains important that 3D imaging for periodontal disease should only be applied when clinically indicated.
- CBCT and MDCT have been shown to be more sensitive in the detection of periapical lesions. However, IOR may suffice in many cases. Several authors consider that limited FOV, high resolution CBCT should only be considered in cases where there are contradictory clinical and radiographic signs and symptoms, non-specific or persistent pain, complex root morphology or extra canals, surgical planning and suspected vertical root fracture not detectable with 2D radiography. The application of MDCT and MRI must also be considered.

- Potentially more complicated or difficult extraction cases may require volumetric imaging, particularly when plain film suggests the tooth is in close proximity to critical structures, such as the mandibular canal or maxillary sinus. While the presence of any of Rood and Shehab's¹ criteria may warrant further radiologic examination, it has been shown that the absence of these radiologic signs does not preclude a close relationship with the inferior alveolar nerve. Diagnostic imaging, including 3D imaging, should only be performed where it has the potential to contribute to diagnosis, prognosis, treatment planning or influences a planned procedure.
- Most authors consider that volumetric imaging should be used in implant planning. Where required, virtual planning and fabrication of computer-generated surgical guides can be performed, based on the scan data sets.
- When indicated, volumetric imaging has been recommended for the assessment of sinus anatomy or pathology, and the preoperative assessment for sinus augmentation or grafting procedures. Plain film imaging for paranasal sinus disease is insufficient. Presently, MDCT remains the most commonly used modality for paranasal sinus disease, considered to be the optimal technique by most clinicians and surgeons.
- MDCT and MRI are appropriate for the evaluation of the bony and soft tissue structures of the TMJ respectively. Some consider that CBCT may be more suitable if soft tissue imaging is not required due to its high bony spatial resolution and reported lower radiation, but factors affecting the image quality must be considered (refer to the aforementioned 'Disadvantages'), especially beam hardening and the relatively low signal-to-noise ratio associated with CBCT scans. Inappropriate selection of the imaging modality can lead to misdiagnosis and a delay in appropriate management.
- MDCT has been recommended over CBCT for more complex, serious or significant cases, especially where there is potential soft tissue involvement. The list includes benign or malignant tumours, cysts, undiagnosed pain, facial fractures, cellulitis, osteomyelitis or osteonecrosis of the jaw. Other tests, including MRI, ultrasound and nuclear medicine must also be considered.
- CBCT use in orthodontics for diagnosis and treatment planning is becoming increasingly popular, but due consideration should be given to the increased lifetime risk of radiation exposure in children/adolescents. Not all CBCT scans are low dose (refer to 'The Technology' on page 13). The appropriate low dose CBCT unit together with appropriate protocols must be employed. Common applications include assessment of impacted canines, root resorption, tooth position and morphology, and craniofacial anomalies.
- It has been reported that volumetric imaging is more accurate than 2D plain radiographs in the evaluation for obstruction in the upper airways and craniofacial structures. Radiological tests, including 3D imaging, should be prescribed only where it has the potential to contribute to diagnosis, prognosis, treatment planning or influences a planned procedure.

INTERPRETATION

- The interpretation of CBCT or MDCT scans require a higher level of knowledge and skill sets than plain film. Prerequisite knowledge includes radiologic anatomy, orofacial pathology, radiologic features of pathoses and a thorough understanding of the limitations of the technique. Appropriate image interrogation is critical. Some authors recommend that these scans should be interpreted by persons with sufficient advanced training. Interpretation is discussed in Chapter 5.

¹ Rood JP, Shehab BA. The radiological prediction of inferior alveolar nerve injury during third molar surgery. The British journal of oral & maxillofacial Surgery 1990 Feb;28(1):20-5.

Chapter 4: Other advanced techniques: MRI, ultrasound and nuclear medicine *

THE TECHNOLOGY

Magnetic resonance imaging

The basis of MRI imaging modality is a magnetic field generated around a patient which aligns spinning nuclei, the majority of which are protons, electromagnetically with the field flux. A radiofrequency pulse is then applied, causing some of the nuclei to absorb energy (resonate), where protons spin in a higher energy state. When the pulse is turned off, relaxation occurs, protons return to the lower energy state and the stored energy is released, which is detected by a receiver coil in the MRI system. These signals are then used to generate the image.

Ultrasonography

This application uses ultrasonic energy (in the range of 7.5–30 MHz) to obtain a topographical map of tissue interfaces at differing depths in the body. A transducer converts electrical energy into sonic energy using piezoelectric crystals. The transducer is held against the body part of interest. This ultrasonic beam interacts with the various tissues which all have different acoustic impedance. Some of the sonic waves will reflect (echo) back to the transducer, generating an electric signal which is used to produce the diagnostic image. Each tissue has a characteristic echo pattern, allowing detection of tissue boundaries or pathological changes within the tissue. Real-time imaging is possible, as the processing of these echoes occur at a rapid enough rate to allow perception of motion.

Nuclear medicine

A functional imaging technique, which detects abnormal metabolic processes in the body, rather than anatomical/morphological changes, which may not be discernible in the early stages of some diseases.

- *Radionuclide imaging*: evaluates tissue function by utilising radioactive atoms or molecules (radionuclides) which emit gamma rays (e.g. Technetium 99m). These radionuclides are combined with a pharmaceutical to form a radiotracer which is distributed to various parts of the body based on their chemical properties. A gamma camera captures the emitted photons, converting them to light, then into a voltage signal for image reconstruction.
- *Single photon emission computed tomography (SPECT)*: Is a method for acquiring tomographic slices through a patient, where a single or dual headed gamma camera rotates around the patient detecting emitted gamma rays. This data is processed via filtered back-projection or iterative

reconstruction algorithms to form axial slices, similar to a CT image.

- *Positron emission tomography (PET)*: Is an imaging technique using positron emitting radionuclides (e.g. ^{11}C , ^{13}N , ^{15}O , ^{18}F) which are usually combined with pharmaceuticals such as glucose or amino acids, to assess metabolic processes in the body. After a set period of time, positron emission decay occurs, and two photons are produced which travel in opposite directions. A PET camera has a ring of detectors which can map the photons that arrive at the same time and this information is used to produce a functional image of organs and tissues.
- There are now hybrid imaging systems where the nuclear medicine images are co-registered with CT or MRI images (i.e. SPECT/CT, PET/CT and PET/MRI) allowing for combined morphological and functional imaging.

ADVANTAGES

MRI

- No ionising radiation.
- Excellent soft tissue contrast compared to X-ray based techniques due to the higher water content in soft tissues. Certain anatomical and pathological structures with greater vascularity and permeability can be enhanced by intravenous paramagnetic contrast agents such as gadolinium.

Ultrasonography

- No ionising radiation.
- Good soft tissue discrimination and sensitivity for superficial mass lesions.
- Colour Doppler sonography for evaluation of blood flow is possible.
- May be a useful alternative for patients who are contraindicated for MRI.

Nuclear medicine

- Evaluates physiologic alterations of tissues.
- Identify early changes of some diseases not demonstrated in other techniques.
- PET has very high spatial resolution and is able to detect very small lesions.

* B Koong, M Lam. With contributing authors: Dr Jerry Moschilla, Radiologist & Nuclear Medicine Specialist and Clinical A/Prof Michael Bynevelt, Neuroradiologist.

DISADVANTAGES

MRI

- Ferromagnetic objects may move, overheat and therefore injure the patient when in the vicinity of the magnetic field. Therefore, this modality is contraindicated for some patients with some implanted metallic objects or medical devices.
- Metals used in dentistry will not move but may distort the image in its vicinity. Titanium implants only cause minor degradation of the image.
- Longer scan times.
- May not be suitable for claustrophobic patients.
- The use of gadolinium-based contrast media must be used with caution in those with renal impairment as this has been associated with nephrogenic systemic fibrosis. Gadolinium deposition within regions of the brain has recently been discovered and is currently being investigated.

Ultrasonography

- Difficulty in imaging deeper structures and structures obscured by bone.

Nuclear medicine

- Associated with ionising radiation.

APPLICATION IN THE OROFACIAL REGION

MRI

- Evaluating of soft tissue anatomy and pathology, characterisation and extent of lesions e.g. evaluating for perineural spread of tumours.
- Additional characterisation of soft tissue components of bone lesions.
- Considered the gold standard in the assessment of the soft tissues of the temporomandibular joint, particularly the articular disc position. Also demonstrates joint effusions, synovitis, marrow oedema, and changes in the adjacent masticatory muscles.
- Implant dentistry: Identifying the location of inferior alveolar neurovascular bundle where multislice CT or cone beam CT is not able to demonstrate the location of the mandibular canal.

Ultrasonography

- Commonly used in the orofacial region for the evaluation of salivary gland, cervical lymph nodes and neck lumps.
- Ultrasound guided fine needle aspiration and core biopsies.
- Other applications in this region include evaluation of the thyroid glands and carotid vessels.

Nuclear medicine

- Osteoblastic metastatic neoplasms involving bone.
- SPECT has been used to assess mandibular growth in patients with asymmetry. The limited specificity of these studies must be considered. Correlation with CT and/or MRI is useful.
- The extent of medication-induced osteonecrosis of the jaw (MRONJ).
- Gallium and radio labelled white cell radionuclide and SPECT/CT imaging is useful in diagnosing base of skull osteomyelitis.
- PET/CT imaging is useful for skeletal imaging for assessment of primary bone tumours, locating metastases in bone and detecting osteomyelitis. It is often correlated with post contrast CT or MRI scans.
- PET/CT is particularly useful for staging squamous cell carcinoma and other head and neck malignancies.

INTERPRETATION

Radiologists, neuro-radiologists, maxillofacial radiologists and nuclear medicine specialists perform the interpretation of these studies.

Chapter 5: Prescription and radiologic interpretation

This chapter summarises the prescription of the various imaging techniques in relation to the more common conditions/clinical situations encountered in dentistry. An introduction to the key responsibilities and principles involved in radiological interpretation is also included.

Abbreviations: IOR – intraoral radiography; OPG – panoramic radiographs; CBCT – cone beam computed tomography; MDCT – multidetector (multislice) computed tomography; MRI – magnetic resonance imaging.

PRESCRIPTION OF THE OPTIMAL IMAGING TECHNIQUE - A SUMMARY:

The various imaging techniques, including the associated radiation dose levels delivered, have been discussed in the preceding chapters. The following summarises the indications in relation to the conditions and clinical scenarios which are more commonly encountered in dentistry:

Dental caries:

- Bitewing radiographs remain the optimal technique – the limitations, especially in relation to sensitivity, are noted and clinical correlation is essential.
- OPGs are considered inadequate – caries cannot be fully excluded.
- CBCT is associated with increased sensitivity, but decreased specificity. Artefact related to restorations is another limitation.

Periodontal disease:

- OPG provides a good overview. The associated limitations compared to the IOR are recognised.
- IOR demonstrates periodontal bone levels and root morphology, but is less accurate than CBCT and MDCT. Limited sensitivity in relation to vertical defects and furcations have also been demonstrated.
- CBCT and MDCT provide 3D information, which allows for more accurate diagnosis and treatment planning. Could be considered for cases with moderate to severe periodontal disease.

Periapical inflammatory disease:

- A periapical radiograph and clinical findings are sufficient for most cases.
- OPG is less sensitive for detecting periapical lesions.
- CBCT and MDCT are more sensitive, should be considered in cases with contradictory findings or non-specific/unresolved pain.
- In rare instances, MRI can be considered where the clinical suspicion for periapical inflammatory lesion is high, but this is not demonstrated with MDCT/CBCT.

Other conditions affecting the jaws:

- For example, cysts, tumours, osteomyelitis, etc.
- MDCT is usually the technique of choice. CBCT may suffice for some lesions.

Orofacial pain:

- Dentoalveolar inflammatory disease is a common cause – clinical findings combined with IOR and/or OPG are sufficient for diagnosis in most cases.
- Dentoalveolar inflammatory lesions contributing to orofacial pain cannot be fully excluded with IOR and OPG.
- MDCT or CBCT should be considered if the cause of pain is not identified clinically and with 2D imaging.
- Volumetric imaging should be considered if other causes for the orofacial pain is suspected, e.g. sinus disease.
- MRI should be considered if diagnosis is not made following volumetric imaging.

Dental implants:

- IOR and OPG may be useful for initial assessment.
- Pre-implant MDCT or CBCT must be considered.
- MRI may be used to identify the location of the inferior alveolar nerve where the mandibular canal borders are not demonstrated with MDCT or CBCT.

Dental extractions/exposure procedures:

- IOR and OPG are appropriate for most cases.
- Volumetric imaging could be considered for more complicated cases or where the tooth is potentially in close relationship to significant anatomic structures, e.g. the mandibular canal.
- Third molar and related morphology including the relationships with the mandibular canal are better demonstrated with volumetric imaging. The indication for CBCT or MDCT is based upon clinical parameters, potential intra-surgical implications and the OPG appearances.
- Ultra-low dose CBCT should be considered for impacted/ectopic canines.

Dental trauma:

- PA radiographs with different horizontal and vertical angulations has been recommended.
- CBCT and MDCT should be considered where 2D imaging is inconclusive, for complex/severe cases of dentoalveolar trauma and where jaw fractures are suspected. MDCT is the technique of choice for more involved facial bone fractures.

Paranasal sinuses:

- OPGs are inadequate – sinus disease cannot be fully excluded with this technique.
- Volumetric imaging (particularly MDCT) is recommended for the assessment of sinus disease.

TMJ:

- OPGs are inadequate – arthropathy cannot be fully excluded with this technique.
- MDCT is optimal for the evaluation of the bony structures. MDCT also demonstrates the soft tissues and the articular disc may be visualised.
- CBCT demonstrates the bony structures – image degradation related to beam hardening must be considered.
- MRI is optimal for the evaluation of the soft tissues related to the TMJs. MRI is also optimal in the evaluation for effusion, synovitis and marrow oedema. Bony structures are also demonstrated although the lower spatial resolution is recognised.

Soft tissue lesions:

- CBCT does not demonstrate the soft tissues sufficiently well.
- MDCT or MRI could be considered. Ultrasound may be useful, especially for more superficial lesions.

RADIOLOGIC INTERPRETATION

All structures included in any imaging must be appropriately evaluated. The practitioner presiding over the radiologic study is responsible for the thorough interpretation of the entire image, not only the region of interest. Should the entirety of the lesion not be included in the initial scan, preliminary interpretation should still be carried out, which can be useful in deciding the optimal imaging technique for further evaluation. Studies have demonstrated the challenges that dentists encounter in relation to the interpretation of OPGs and CBCT scans.

Volumetric data requires a different level of knowledge and skill for interpretation. Several authors recommend that CBCT scans should be interpreted by persons with sufficient advanced training.

The following publications introduce the key principles of radiologic interpretation:

Koong B. The basic principles of radiological interpretation. *Aust Dent J.* 2012;57 Suppl 1:33–9.

Koong B. Diagnostic imaging of the periodontal and implant patient. In Lang PL & Lindhe J (eds.), *Clinical periodontology and implant dentistry* (6th edition., 574–608). UK: Wiley Blackwell.

Some of the key points, based upon these two publications, are summarised:

Prerequisites:

- *Radiologic anatomy:* An in-depth knowledge of anatomy and their normal variants is critical. Knowledge of the appearances of all normal structures will aid in identifying the presence of pathology.
- *Pathology:* Knowledge of the pathology which may occur in all regions included in the field of view or scan, as well as the radiologic appearances of these lesions, is obviously of importance.
- *Imaging modality:* Understanding the strengths and limitations of the various imaging techniques impacts on the interpretation of the studies. Examples include the tomographic nature of OPGs and beam hardening seen in CBCT scans.
- *Viewing conditions:* The lighting conditions and display quality of the monitor can have a significant influence on the accuracy of the radiologic interpretation. This was covered in Chapter 1 of this series.

Identifying the presence of disease

- A methodical approach during evaluation of the entire image or dataset is critical.
- The interrogation of volumetric data requires a different skill set to that for plain 2D films.

Radiologic evaluation of a lesion(s)

An algorithm should be followed to identify the relevant radiologic features. Below is an example:

1. Location
2. Shape and contour
3. Border
4. Internal appearances
5. Adjacent anatomical structures

Lesions will not always present classically, nor will they necessarily demonstrate all the typical features. As a result, it is necessary to weigh the identified features. For example, a lucency at the apex of a tooth is often inflammatory in nature. However, a malignant lesion may also present as a lucent lesion apically and weight must be given to the marginal appearances.

CONCLUSION

As advances in diagnostic imaging continue, it is increasingly essential that clinicians remain up-to-date in order to prescribe the optimal radiological test for their patients. The practitioner presiding over the radiologic study is responsible for the examination in its entirety and should ensure that it is interpreted by appropriately skilled persons.

Further reading

Ahmad M, Jenny J, Downie M. Application of cone beam computed tomography in oral and maxillofacial surgery. *Aust Dent J*. 2012;57:82–94.

Ahmed F, Brooks SL, Kapila SD. Efficacy of identifying maxillofacial lesions in cone-beam computed tomographs by orthodontists and orthodontic residents with third-party software. *Am J Orthod Dentofacial Orthop*. 2012 Apr;141(4):451–9; [Internet] Available from: <http://dx.doi.org/10.1016/j.ajodo.2011.10.025>.

Akdeniz BG, Gröndahl H-G, Magnusson B. Accuracy of proximal caries depth measurements: comparison between limited cone beam computed tomography, storage phosphor and film radiography. *Caries Res*. 2006;40(3):202–7.

Akdeniz BG, Gröndahl H-G. Degradation of storage phosphor images due to scanning delay. *Dentomaxillofac Radiol*. 2006 Mar;35(2):74–7.

Akkaya N, Kansu Ö, Kansu H, Çağırankaya LB, Arslan U. Comparing the accuracy of panoramic and intraoral radiography in the diagnosis of proximal caries. *Dentomaxillofacial Radiology*. 2006;35(3):170–4.

Al-Ekrish AA, Ekram M. A comparative study of the accuracy and reliability of multidetector computed tomography and cone beam computed tomography in the assessment of dental implant site dimensions. *Dentomaxillofac Radiol*. 2011 Feb;40(2):67–75.

Alqerban A, Hedesiu M, Baciut M, Nackaerts O, Jacobs R, Fieuws S, et al. Pre-surgical treatment planning of maxillary canine impactions using panoramic vs cone beam CT imaging. *Dentomaxillofac Radiol*. 2013 Aug 1;42(9):20130157.

Alqerban A, Jacobs R, Fieuws S, Willems G. Comparison of two cone beam computed tomographic systems versus panoramic imaging for localization of impacted maxillary canines and detection of root resorption. *Eur J Orthod*. 2011 Feb;33(1):93–102.

Alsufyani NA, Flores-Mir C, Major PW. Three-dimensional segmentation of the upper airway using cone beam CT: a systematic review. *Dentomaxillofac Radiol*. 2012 May;41(4):276–84.

American Academy of Oral and Maxillofacial Radiology. Clinical recommendations regarding use of cone beam computed tomography in orthodontics. [corrected]. Position statement by the American Academy of Oral and Maxillofacial Radiology. *Oral Surg Oral Med Oral Pathol Oral Radiol*. 2013 Aug;116(2):238–57.

American Dental Association Council on Scientific Affairs. Dental Radiographic Examinations: Recommendations for Patient Selection and Limiting Radiation Exposure [Internet]. 2012. Available from: http://www.ada.org/~media/ADA/Member%20Center/Files/Dental_Radiographic_Examinations_2012.pdf

Angelopoulos C, Aghaloo T. Imaging technology in implant diagnosis. *Dent Clin North Am*. 2011 Jan;55(1):141–58.

Anthonappa RP, King NM, Rabie ABM, Mallineni SK. Reliability of panoramic radiographs for identifying supernumerary teeth in children. *Int J Paediatr Dent*. 2012 Jan;22(1):37–43.

Apostolakis D, Brown JE. The anterior loop of the inferior alveolar nerve: prevalence, measurement of its length and a recommendation for interforaminal implant installation based on cone beam CT imaging. *Clin Oral Implants Res*. 2012;23(9):1022–30.

Atieh MA. Diagnostic accuracy of panoramic radiography in determining relationship between inferior alveolar nerve and mandibular third molar. *J Oral Maxillofac Surg*. 2010 Jan;68(1):74–82.

Australian Radiation Protection and Nuclear Safety Agency. Radiation Protection and Dentistry. Code of Practice and Safety Guide [Internet]. 2005 Dec. Available from: <http://content.arpansa.gov.au/pubs/rps/rps10.pdf>

Baciut M, Hedesiu M, Bran S, Jacobs R, Nackaerts O, Baciut G. Pre- and postoperative assessment of sinus grafting procedures using cone-beam computed tomography compared with panoramic radiographs. *Clin Oral Implants Res*. 2013 May;24(5):512–6.

Barghan S, Tetradis S, Mallya SM. Application of cone beam computed tomography for assessment of the temporomandibular joints. *Aust Dent J*. 2012;57:109–18.

Bayat S, Talaeipour AR, Sarlati F. Detection of simulated periodontal defects using cone-beam CT and digital intraoral radiography. *Dentomaxillofac Radiol*. 2016 May 18;20160030. Bedard A, Davis TD, Angelopoulos C. Storage phosphor plates: how durable are they as a digital dental radiographic system? *J Contemp Dent Pract*. 2004 May 15;5(2):57–69.

Benic GI, Elmasry M, Hämmerle CHF. Novel digital imaging techniques to assess the outcome in oral rehabilitation with dental implants: a narrative review. *Clin Oral Implants Res*. 2015 Sep;26 Suppl 11:86–96.

Berkhout W, Beuger DA, Sanderink G, van der Stelt PF. The dynamic range of digital radiographic systems: dose reduction or risk of overexposure? *Dentomaxillofacial Radiology*. 2004;33(1):1–5.

Bornstein MM, Wölner-Hanssen AB, Sendi P, von Arx T. Comparison of intraoral radiography and limited cone beam computed tomography for the assessment of root-fractured permanent teeth. *Dent Traumatol.* 2009 Dec;25(6):571–7. Botticelli S, Verna C, Cattaneo PM, Heidmann J, Melsen B. Two-versus three-dimensional imaging in subjects with unerupted maxillary canines. *Eur J Orthod.* 2011 Aug;33(4):344–9.

Braun X, Ritter L, Jervøe-Storm P-M, Frentzen M. Diagnostic accuracy of CBCT for periodontal lesions. *Clin Oral Investig.* 2014 May;18(4):1229–36.

Butt A, Mahoney M, Savage NW. The impact of computer display performance on the quality of digital radiographs: a review. *Aust Dent J.* 2012 Mar;57 Suppl 1:16–23.

Carter L, Farman AG, Geist J, Scarfe WC, Angelopoulos C, Nair MK, et al. American Academy of Oral and Maxillofacial Radiology executive opinion statement on performing and interpreting diagnostic cone beam computed tomography. *Oral Surgery, Oral Med Oral Pathol Oral Radiol Endodontology.* 2008;106(4):561–2.

Chapokas AR, Almas K, Schincaglia G-P. The impacted maxillary canine: a proposed classification for surgical exposure. *Oral Surg Oral Med Oral Pathol Oral Radiol.* 2012;113(2):222–8.

Cimino R, Steenks MH, Michelotti A, Farella M, PierFrancesco N. Mandibular condyle osteochondroma. Review of the literature and report of a misdiagnosed case. *J Orofac Pain.* 2003 Summer;17(3):254–61.

Cohenca N, Simon JH, Roges R, Morag Y, Malfaz JM. Clinical indications for digital imaging in dento-alveolar trauma. Part 1: traumatic injuries. *Dent Traumatol.* 2007 Apr;23(2):95–104.

Crane GD, Abbott PV. Radiation shielding in dentistry: an update. *Aust Dent J.* 2016 Sep;61(3):277–81.

Davis AT, Safi H, Maddison SM. The reduction of dose in paediatric panoramic radiography: the impact of collimator height and programme selection. *Dentomaxillofac Radiol.* 2015;44(2):20140223.

de Faria Vasconcelos K, Evangelista KM, Rodrigues CD, Estrela C, de Sousa TO, Silva MAG. Detection of periodontal bone loss using cone beam CT and intraoral radiography. *Dentomaxillofac Radiol.* 2012 Jan;41(1):64–9.

De Vos W, Casselman J, Swennen GRJ. Cone-beam computerized tomography (CBCT) imaging of the oral and maxillofacial region: a systematic review of the literature. *Int J Oral Maxillofac Surg.* 2009 Jun;38(6):609–25.

Diangelis AJ, Andreasen JO, Ebeleseder KA, Kenny DJ, Trope M, Sigurdsson A, et al. International Association of Dental

Traumatology guidelines for the management of traumatic dental injuries: 1. Fractures and luxations of permanent teeth. *Dent Traumatol.* 2012 Feb;28(1):2–12.

dos Santos Corpas L, Jacobs R, Quirynen M, Huang Y, Naert I, Duyck J. Peri-implant bone tissue assessment by comparing the outcome of intra-oral radiograph and cone beam computed tomography analyses to the histological standard. *Clin Oral Implants Res.* 2010;22(5):492–9.

du Bois AH, Kardachi B, Bartold PM. Is there a role for the use of volumetric cone beam computed tomography in periodontics? *Aust Dent J.* 2012 Mar;57 Suppl 1:103–8.

Dula K, Sanderink G, van der Stelt PF, Mini R, Buser D. Effects of dose reduction on the detectability of standardized radiolucent lesions in digital panoramic radiography. *Oral Surg Oral Med Oral Pathol Oral Radiol Endod.* 1998 Aug;86(2):227–33.

Ergün S, Güneri P, Ilgüy D, Ilgüy M, Boyacioglu H. How many times can we use a phosphor plate? A preliminary study. *Dentomaxillofac Radiol.* 2009 Jan;38(1):42–7.

Estrela C, Bueno MR, Leles CR, Azevedo B, Azevedo JR. Accuracy of cone beam computed tomography and panoramic and periapical radiography for detection of apical periodontitis. *J Endod.* 2008 Mar;34(3):273–9.

European Commission, Sedentext. Radiation Protection 172: Cone Beam CT for Dental and Maxillofacial Radiology - Evidence-based Guidelines [Internet]. 2012. Available from: http://www.sedentext.eu/files/radiation_protection_172.pdf European Commission. Radiation Protection 136. European guidelines on radiation protection in dental radiology [Internet]. 2004 [cited 2017 Sep 24]. Available from: https://ec.europa.eu/energy/sites/ener/files/documents/136_0.pdf

Evans C a., Scarfe WC, Ahmad M, Cevidanes LHS, Ludlow JB, Palomo JM, et al. Clinical recommendations regarding use of cone beam computed tomography in orthodontics. Position statement by the American Academy of Oral and Maxillofacial Radiology. *Oral Surg Oral Med Oral Pathol Oral Radiol* [Internet]. 2013;116(2):238– 57. Available from: <http://www.ncbi.nlm.nih.gov/pubmed/23849378>

Fallon SD, Fritz GW, Laskin DM. Panoramic imaging of the temporomandibular joint: an experimental study using cadaveric skulls. *J Oral Maxillofac Surg.* 2006 Feb;64(2):223–9.

Farman AG, Farman TT. A comparison of 18 different x-ray detectors currently used in dentistry. *Oral Surg Oral Med Oral Pathol Oral Radiol Endod.* 2005 Apr;99(4):485–9.

Farman AG, Farman TT. A comparison of image characteristics and convenience in panoramic radiography using charge-

coupled device, storage phosphor, and film receptors. *J Digit Imaging*. 2001 Jun;14(2 Suppl 1):48–51.

Fatemitabar SA, Nikgoo A. Multichannel computed tomography versus cone-beam computed tomography: linear accuracy of in vitro measurements of the maxilla for implant placement. *Int J Oral Maxillofac Implants*. 2010 May;25(3):499–505.
Fayad MI, Nair M, Levin MD, Benavides E, Rubinstein RA, Barghan S, et al. AAE and AAOMR Joint Position Statement Use of Cone Beam Computed Tomography in Endodontics 2015 Update. Vol. 120, *Oral Surgery, Oral Medicine, Oral Pathology and Oral Radiology*. 2015. p. 508–12.

Fortin T, Camby E, Alik M, Isidori M, Bouchet H. Panoramic images versus three-dimensional planning software for oral implant planning in atrophied posterior maxillary: a clinical radiological study. *Clin Implant Dent Relat Res*. 2013 Apr;15(2):198–204.

Fuhrmann RAW, Bucker A, Diedrich PR. Assessment of alveolar bone loss with high resolution computed tomography. *J Periodontal Res*. 1995;30(4):258–63.

Gaalaas L, Tyndall D, Mol A, Everett ET, Bangdiwala A. Ex vivo evaluation of new 2D and 3D dental radiographic technology for detecting caries. *Dentomaxillofac Radiol*. 2016;45(3):20150281.

Gavala S, Donta C, Tsiklakis K, Boziari A, Kamenopoulou V, Stamatakis HC. Radiation dose reduction in direct digital panoramic radiography. *Eur J Radiol*. 2009 Jul;71(1):42–8.

Gijbels F, Jacobs R, Bogaerts R, Debaveye D, Verlinden S, Sanderink G. Dosimetry of digital panoramic imaging. Part I: Patient exposure. *Dentomaxillofac Radiol*. 2005 May;34(3):145–9.

Granlund C, Thilander-Klang A, Ylhan B, Lofthag-Hansen S, Ekestubbe A. Absorbed organ and effective doses from digital intra-oral and panoramic radiography applying the ICRP 103 recommendations for effective dose estimations. *Br J Radiol*. 2016 Oct;89(1066):20151052.

Grimard BA, Hoidal MJ, Mills MP, Mellonig JT, Nummikoski PV, Mealey BL. Comparison of Clinical, Periapical Radiograph, and Cone-Beam Volume Tomography Measurement Techniques for Assessing Bone Level Changes Following Regenerative Periodontal Therapy. *J Periodontol*. 2009;80(1):48–55.
Guerrero ME, Noriega J, Castro C, Jacobs R. Does cone-beam CT alter treatment plans? Comparison of preoperative implant planning using panoramic versus cone-beam CT images. *Imaging Sci Dent*. 2014 Jun;44(2):121–8.

Guerrero ME, Noriega J, Jacobs R. Preoperative implant planning considering alveolar bone grafting needs and complication prediction using panoramic versus CBCT images. *Imaging Sci Dent*. 2014;44(3):213.

Gundappa M, Ng SY, Whaites EJ. Comparison of ultrasound, digital and conventional radiography in differentiating periapical lesions. *Dentomaxillofac Radiol*. 2006 Sep;35(5):326–33.

Haak R, Wicht MJ. Grey-scale reversed radiographic display in the detection of approximal caries. *J Dent*. 2005 Jan;33(1):65–71.

Haas LF, Dutra K, Porporatti AL, Mezzomo LA, De Luca Canto G, Flores-Mir C, et al. Anatomical variations of mandibular canal detected by panoramic radiography and CT: a systematic review and meta-analysis. *Dentomaxillofacial Radiology*. 2016;45(2):20150310.

Haiter-Neto F, Wenzel A, Gotfredsen E. Diagnostic accuracy of cone beam computed tomography scans compared with intraoral image modalities for detection of caries lesions. *Dentomaxillofac Radiol*. 2008 Jan;37(1):18–22.

Halperin-Sternfeld M, Machtei EE, Horwitz J. Diagnostic accuracy of cone beam computed tomography for dimensional linear measurements in the mandible. *Int J Oral Maxillofac Implants*. 2014 May;29(3):593–9.

Haney E, Gansky SA, Lee JS, Johnson E, Maki K, Miller AJ, et al. Comparative analysis of traditional radiographs and cone-beam computed tomography volumetric images in the diagnosis and treatment planning of maxillary impacted canines. *Am J Orthod Dentofacial Orthop*. 2010 May;137(5):590–7; internet Available from: <http://dx.doi.org/10.1016/j.ajodo.2008.06.035>

Harris D, Horner K, Gröndahl K, Jacobs R, Helmrot E, Benic GI, et al. E.A.O. guidelines for the use of diagnostic imaging in implant dentistry 2011. A consensus workshop organized by the European Association for Osseointegration at the Medical University of Warsaw. *Clin Oral Implants Res*. 2012;23(11):1243–53.

Hatcher DC. Cone beam computed tomography: craniofacial and airway analysis. *Dent Clin North Am*. 2012 Apr;56(2):343–57.

Hayashi T. Application of ultrasonography in dentistry. *Jpn Dent Sci Rev*. 2012;48(1):5–13.

Heitz-Mayfield LJA. Diagnosis and management of peri-implant diseases. *Aust Dent J*. 2008 Jun;53 Suppl 1:S43–8.

Hellén-Halme K, Nilsson M, Petersson A. Effect of monitors on approximal caries detection in digital radiographs—standard versus precalibrated DICOM part 14 displays: an in vitro study. *Oral Surg Oral Med Oral Pathol Oral Radiol Endod*. 2009 May;107(5):716–20.

Hellén-Halme K, Petersson A, Warfvinge G, Nilsson M. Effect of ambient light and monitor brightness and contrast settings on

the detection of approximal caries in digital radiographs: an in vitro study. *Dentomaxillofacial Radiology*. 2008;37(7):380–4.

Heo M-S, An B-M, Lee S-S, Choi S-C. Use of advanced imaging modalities for the differential diagnosis of pathoses mimicking temporomandibular disorders. *Oral Surg Oral Med Oral Pathol Oral Radiol Endod*. 2003 Nov;96(5):630–8.

Hintze H, Wiese M, Wenzel A. Comparison of three radiographic methods for detection of morphological temporomandibular joint changes: panoramic, scanographic and tomographic examination. *Dentomaxillofac Radiol*. 2009 Mar;38(3):134–40.

Hofmann E, Schmid M, Lell M, Hirschfelder U. Cone beam computed tomography and low-dose multislice computed tomography in orthodontics and dentistry. *J Orofac Orthop*. 2014;75(5):384–98.

Honey OB, Scarfe WC, Hilgers MJ, Klueber K, Silveira AM, Haskell BS, et al. Accuracy of cone-beam computed tomography imaging of the temporomandibular joint: comparisons with panoramic radiology and linear tomography. *Am J Orthod Dentofacial Orthop*. 2007 Oct;132(4):429–38.

Horner K, Islam M, Flygare L, Tsiklakis K, Whaites E. Basic principles for use of dental cone beam computed tomography: Consensus guidelines of the European Academy of Dental and Maxillofacial Radiology. *Dentomaxillofac Radiol*. 2009;38(4):187–95.

Hunter A, Kalathingal S. Diagnostic Imaging for Temporomandibular Disorders and Orofacial Pain. *Dent Clin North Am*. 2013;57(3):405–18.

Hussain AM, Packota G, Major PW, Flores-Mir C. Role of different imaging modalities in assessment of temporomandibular joint erosions and osteophytes: a systematic review. *Dentomaxillofac Radiol*. 2008 Feb;37(2):63–71.

Huomonen S, Kvist T, Gröndahl K, Molander A. Diagnostic value of computed tomography in re-treatment of root fillings in maxillary molars. *Int Endod J*. 2006 Oct;39(10):827–33.

Ikubo M, Kobayashi K, Mishima A, Shimoda S, Daimaruya T, Igarashi C, et al. Accuracy of intraoral radiography, multidetector helical CT, and limited cone-beam CT for the detection of horizontal tooth root fracture. *Oral Surgery, Oral Medicine, Oral Pathology, Oral Radiology, and Endodontology*. 2009;108(5):e70–4.

Isidor S, Faaborg-Andersen M, Hintze H, Kirkevang L-L, Frydenberg M, Hailer-Neto F, et al. Effect of monitor display on detection of approximal caries lesions in digital radiographs. *Dentomaxillofac Radiol*. 2009 Dec;38(8):537–41.

Jacobs R, Quirynen M. Dental cone beam computed tomography: justification for use in planning oral implant placement. *Periodontol* 2000. 2014 Oct;66(1):203–13.

Jawad Z, Carmichael F, Houghton N, Bates C. A review of cone beam computed tomography for the diagnosis of root resorption associated with impacted canines, introducing an innovative root resorption scale. *Oral Surg Oral Med Oral Pathol Oral Radiol*. 2016;122(6):765–71.

Jhamb A, Dolas RS, Pandilwar PK, Mohanty S. Comparative efficacy of spiral computed tomography and orthopantomography in preoperative detection of relation of inferior alveolar neurovascular bundle to the impacted mandibular third molar. *J Oral Maxillofac Surg*. 2009 Jan;67(1):58–66.

Jonsson MV, Baldini C. Major Salivary Gland Ultrasonography in the Diagnosis of Sjögren's Syndrome. *Rheum Dis Clin North Am*. 2016;42(3):501–17.

Kaepler G, Dietz K, Herz K, Reinert S. Factors influencing the absorbed dose in intraoral radiography. *Dentomaxillofac Radiol*. 2007 Dec;36(8):506–13.

Kalathingal SM, Mol A, Tyndall DA, Caplan DJ. In vitro assessment of cone beam local computed tomography for proximal caries detection. *Oral Surg Oral Med Oral Pathol Oral Radiol Endod*. 2007 Nov;104(5):699–704.

Kallio-Pulkkinen S, Huomonen S, Haapea M, Liukkonen E, Sipola A, Tervonen O, et al. Effect of display type, DICOM calibration and room illuminance in bitewing radiographs. *Dentomaxillofac Radiol*. 2016;45(1):20150129.

Kamburoglu K, Kolsuz E, Murat S, Yüksel S, Ozen T. Proximal caries detection accuracy using intraoral bitewing radiography, extraoral bitewing radiography and panoramic radiography. *Dentomaxillofac Radiol*. 2012 Sep;41(6):450–9.

Kamburoğlu K, Murat S, Yüksel SP, Cebeci ARİ, Paksoy CS. Occlusal caries detection by using a cone-beam CT with different voxel resolutions and a digital intraoral sensor. *Oral Surgery, Oral Medicine, Oral Pathology, Oral Radiology, and Endodontology*. 2010;109(5):e63–9.

Khambete N, Kumar R. Ultrasound in differential diagnosis of periapical radiolucencies: A radiohistopathological study. *J Conserv Dent*. 2015 Jan;18(1):39–43.

Kim Y-K, Park J-Y, Kim S-G, Kim J-S, Kim J-D. Magnification rate of digital panoramic radiographs and its effectiveness for pre-operative assessment of dental implants. *Dentomaxillofac Radiol*. 2011 Feb;40(2):76–83.

Koong B. *Atlas of Oral and Maxillofacial Radiology*. Wiley-Blackwell; 2017.

Koong B. Cone beam imaging: is this the ultimate imaging modality? *Clin Oral Implants Res.* 2010 Nov;21(11):1201–8.

Koong B. Diagnostic imaging of the periodontal and implant patient. In Lang PL & Lindhe J (eds.), *Clinical periodontology and implant dentistry* (6th edition., 574-608). UK: Wiley Blackwell.

Koong B. The basic principles of radiological interpretation. *Aust Dent J.* 2012 Mar;57 Suppl 1:33–9;57:33–9.

Korostoff J, Aratsu A, Kasten B, Mupparapu M. Radiologic Assessment of the Periodontal Patient. *Dent Clin North Am.* 2016 Jan;60(1):91–104.

Kositbowornchai S, Densiri-aksorn W, Piumthanaroj P. Ability of two radiographic methods to identify the closeness between the mandibular third molar root and the inferior alveolar canal: a pilot study. *Dentomaxillofacial Radiology.* 2010;39(2):79–84.

Krzyżostaniak J, Surdacka A, Kulczyk T, Dyszkiewicz-Konwińska M, Owecka M. Diagnostic accuracy of cone beam computed tomography compared with intraoral radiography for the detection of noncavitated occlusal carious lesions. *Caries Res.* 2014 May 21;48(5):461–6.

Kullman L, Al Sane M. Guidelines for dental radiography immediately after a dento-alveolar trauma, a systematic literature review. *Dent Traumatol.* 2012 Jun;28(3):193–9.

Ladeira DBS, da Cruz AD, de Almeida SM. Digital panoramic radiography for diagnosis of the temporomandibular joint: CBCT as the gold standard. *Braz Oral Res.* 2015 Oct 9;29(1):S1806–83242015000100303.

Lang NP, Lindhe J. *Clinical Periodontology and Implant Dentistry.* Sixth Edition. Chichester: John Wiley & Sons, Ltd.; 2015.

Langen HJ, Fuhrmann R, Diedrich P, Günther RW. Diagnosis of infra-alveolar bony lesions in the dentate alveolar process with high-resolution computed tomography. Experimental results. *Invest Radiol.* 1995 Jul;30(7):421–6.

Larheim TA, Abrahamsson A-K, Kristensen M, Arvidsson LZ. Temporomandibular joint diagnostics using CBCT. *Dentomaxillofac Radiol.* 2015;44(1):20140235.

Lenza MG, Lenza MM de O, Dalstra M, Melsen B, Cattaneo PM. An analysis of different approaches to the assessment of upper airway morphology: a CBCT study. *Orthod Craniofac Res.* 2010 May;13(2):96–105.

Liang X, Jacobs R, Hassan B, Li L, Pauwels R, Corpas L, et al. A comparative evaluation of Cone Beam Computed Tomography (CBCT) and Multi-Slice CT (MSCT) Part I. On subjective image quality. *Eur J Radiol.* 2010 Aug;75(2):265–9.

Liu D-G, Zhang W-L, Zhang Z-Y, Wu Y-T, Ma X-C. Localization of impacted maxillary canines and observation of adjacent incisor resorption with cone-beam computed tomography. *Oral Surg Oral Med Oral Pathol Oral Radiol Endod.* 2008 Jan;105(1):91–8.

Long H, Zhou Y, Ye N, Liao L, Jian F, Wang Y, et al. Diagnostic accuracy of CBCT for tooth fractures: a meta-analysis. *J Dent.* 2014 Mar;42(3):240–8.

Lopes LJ, Gamba TO, Bertinato JVI, Freitas DQ. Comparison of panoramic radiography and CBCT to identify maxillary posterior roots invading the maxillary sinus. *Dentomaxillofac Radiol.* 2016 Jun 8;45(6):20160043.

Loubele M, Bogaerts R, Van Dijck E, Pauwels R, Vanheusden S, Suetens P, et al. Comparison between effective radiation dose of CBCT and MSCT scanners for dentomaxillofacial applications. *Eur J Radiol.* 2009 Sep;71(3):461–8.

Loubele M, Van Assche N, Carpentier K, Maes F, Jacobs R, van Steenberghe D, et al. Comparative localized linear accuracy of small-field cone-beam CT and multislice CT for alveolar bone measurements. *Oral Surg Oral Med Oral Pathol Oral Radiol Endod.* 2008 Apr;105(4):512–8.

Luangchana P, Pornprasertsuk-Damrongsri S, Kiattavorncharoen S, Jirajariyavej B. Accuracy of linear measurements using cone beam computed tomography and panoramic radiography in dental implant treatment planning. *Int J Oral Maxillofac Implants.* 2015 Nov;30(6):1287–94.

Ludlow JB, Davies-Ludlow LE, White SC. Patient Risk Related to Common Dental Radiographic Examinations. *The Journal of the American Dental Association.* 2008;139(9):1237–43.

Ludlow JB, Ivanovic M. Comparative dosimetry of dental CBCT devices and 64-slice CT for oral and maxillofacial radiology. *Oral Surg Oral Med Oral Pathol Oral Radiol Endod.* 2008 Jul;106(1):106–14.

Ludlow JB, Timothy R, Walker C, Hunter R, Benavides E, Samuelson DB, et al. Effective dose of dental CBCT—a meta analysis of published data and additional data for nine CBCT units. *Dentomaxillofacial Radiology.* 2015;44(1):20140197.

Malina-Altzinger J, Damerau G, Grätz KW, Stadlinger PDB. Evaluation of the maxillary sinus in panoramic radiography—a comparative study. *International Journal of Implant Dentistry [Internet].* 2015;1(1). Available from: <http://dx.doi.org/10.1186/s40729-015-0015-1>

Marotti J, Heger S, Tinschert J, Tortamano P, Chuembou F, Radermacher K, et al. Recent advances of ultrasound imaging in dentistry—a review of the literature. *Oral Surg Oral Med Oral Pathol Oral Radiol.* 2013 Jun;115(6):819–32.

Mattos CT, Cruz CV, da Matta TCS, Pereira L de A, Solon-de-Mello P de A, Ruellas AC de O, et al. Reliability of upper airway linear, area, and volumetric measurements in cone-beam computed tomography. *Am J Orthod Dentofacial Orthop.* 2014 Feb;145(2):188–97.

Matzen LH, Wenzel A. Efficacy of CBCT for assessment of impacted mandibular third molars: a review - based on a hierarchical model of evidence. *Dentomaxillofac Radiol.* 2015;44(1):20140189.

May JJ, Cohenca N, Peters OA. Contemporary Management of Horizontal Root Fractures to the Permanent Dentition: Diagnosis—Radiologic Assessment to Include Cone-Beam Computed Tomography. *J Endod.* 2013;39(3):S20–5.

McIlgorm D. Viewing your digital radiographs: which monitor is best? *Br Dent J.* 2016 Apr 22;220(8):393–7.

McNab S, Monsour P, Madden D, Gannaway D. Knowledge of Undergraduate and Graduate Dentists and Dental Therapists concerning Panoramic Radiographs : Knowledge of Panoramic Radiographs. *Open Journal of Dentistry and Oral Medicine.* 2015;3(2):46–52.

Metsälä E, Henner A, Ekholm M. Quality assurance in digital dental imaging: a systematic review. *Acta Odontol Scand.* 2014 Jul;72(5):362–71.

Mischkowski RA, Ritter L, Neugebauer J, Dreiseidler T, Keeve E, Zöllner JE. Diagnostic quality of panoramic views obtained by a newly developed digital volume tomography device for maxillofacial imaging. *Quintessence Int.* 2007 Oct;38(9):763–72.

Møystad A, Svanaes DB, Larheim TA, Gröndahl HG. Effect of image magnification of digitized bitewing radiographs on approximal caries detection: an in vitro study. *Dentomaxillofac Radiol.* 1995 Nov;24(4):255–9.

Mupparapu M, Nadeau C. Oral and Maxillofacial Imaging. *Dent Clin North Am.* 2016;60(1):1–37.

Nakamori K, Fujiwara K, Miyazaki A, Tomihara K, Tsuji M, Nakai M, et al. Clinical assessment of the relationship between the third molar and the inferior alveolar canal using panoramic images and computed tomography. *J Oral Maxillofac Surg.* 2008 Nov;66(11):2308–13.

Nardi C, Calistri L, Pradella S, Desideri I, Lorini C, Colagrande S. Accuracy of Orthopantomography for Apical Periodontitis without Endodontic Treatment. *J Endod.* 2017 Oct;43(10):1640–6.

National Electrical Manufacturers Association. Digital Imaging and Communications in Medicine (DICOM) Part 14: Grayscale Standard Display Function [Internet]. 2004 [cited 2017 Aug 10]. Available from: http://dicom.nema.org/dicom/2004/04_14pu.pdf

Neves FS, Souza TC, Almeida SM, Haiter-Neto F, Freitas DQ, Bóscolo FN. Correlation of panoramic radiography and cone beam CT findings in the assessment of the relationship between impacted mandibular third molars and the mandibular canal. *Dentomaxillofac Radiol.* 2012 Oct;41(7):553–7.

Obinata K, Sato T, Ohmori K, Shindo M, Nakamura M. A comparison of diagnostic tools for Sjögren syndrome, with emphasis on sialography, histopathology, and ultrasonography. *Oral Surg Oral Med Oral Pathol Oral Radiol Endod.* 2010 Jan;109(1):129–34.

Okano T, Sur J. Radiation dose and protection in dentistry. *Jpn Dent Sci Rev.* 2010;46(2):112–21.

Park W, Nam W, Park H-S, Kim HJ. Intraosseous lesion in mandibular condyle mimicking temporomandibular disorders: report of 3 cases. *J Orofac Pain.* 2008 Winter;22(1):65–70.
Park Y-S, Ahn J-S, Kwon H-B, Lee S-P. Current status of dental caries diagnosis using cone beam computed tomography. *Imaging Sci Dent.* 2011 Jun;41(2):43–51.

Parks ET, Williamson GF. Digital radiography: an overview. *J Contemp Dent Pract.* 2002 Nov 15;3(4):23–39.

Patel S, Wilson R, Dawood A, Mannoce F. The detection of periapical pathosis using periapical radiography and cone beam computed tomography - part 1: pre-operative status. *Int Endod J.* 2012 Aug;45(8):702–10.

Pauwels R, Araki K, Siewerdsen JH, Thongvigitmanee SS. Technical aspects of dental CBCT: state of the art. *Dentomaxillofac Radiol.* 2015;44(1):20140224.

Pauwels R, Jacobs R, Singer SR, Mupparapu M. CBCT-based bone quality assessment: are Hounsfield units applicable? *Dentomaxillofac Radiol.* 2015;44(1):20140238.

Pauwels R. Cone beam CT for dental and maxillofacial imaging: dose matters. *Radiat Prot Dosimetry.* 2015 Jul;165(1-4):156–61.

Pauwels R. Cone beam CT for dental and maxillofacial imaging: dose matters: Table 1. *Radiat Prot Dosimetry.* 2015;165(1-4):156–61.

Perschbacher S. Interpretation of panoramic radiographs. *Aust Dent J.* 2012;57:40–5.

Qiao J, Wang S, Duan J, Zhang Y, Qiu Y, Sun C, et al. The accuracy of cone-beam computed tomography in assessing maxillary molar furcation involvement. *J Clin Periodontol.* 2014 Mar;41(3):269–74.

Raghav N, Reddy SS, Giridhar AG, Murthy S, Yashodha Devi BK, Santana N, et al. Comparison of the efficacy of conventional radiography, digital radiography, and ultrasound in diagnosing

periapical lesions. *Oral Surg Oral Med Oral Pathol Oral Radiol Endod.* 2010 Sep;110(3):379–85.

Rood JP, Shehab BA. The radiological prediction of inferior alveolar nerve injury during third molar surgery. *The British journal of oral & maxillofacial Surgery* 1990 Feb;28(1):20-5.

Rushton MN, Rushton VE. A study to determine the added value of 740 screening panoramic radiographs compared to intraoral radiography in the management of adult (>18 years) dentate patients in a primary care setting. *J Dent.* 2012 Aug;40(8):661–9.

Rushton V, Horner K, Worthington H. Screening panoramic radiology of adults in general dental practice: radiological findings. *Br Dent J.* 2001;190(9):495–501; internet available from: <http://www.nature.com/doi/10.1038/sj.bdj.4801014a>

Rushton VE, Horner K. The use of panoramic radiology in dental practice. *J Dent.* 1996;24(3):185–201.

Salineiro FCS, Gialain IO, Kobayashi-Velasco S, Pannuti CM, Cavalcanti MGP. Detection of furcation involvement using periapical radiography and 2 cone-beam computed tomography imaging protocols with and without a metallic post: An animal study. *Imaging Sci Dent.* 2017 Mar;47(1):17–24.

Scarfe WC, Li Z, Aboelmaaty W, Scott SA, Farman AG. Maxillofacial cone beam computed tomography: essence, elements and steps to interpretation. *Aust Dent J.* 2012 Mar;57 Suppl 1:46–60.

Scherer MD. Presurgical implant-site assessment and restoratively driven digital planning. *Dent Clin North Am.* 2014 Jul;58(3):561–95.

Schmitter M, Gabbert O, Ohlmann B, Hassel A, Wolff D, Rammelsberg P, et al. Assessment of the reliability and validity of panoramic imaging for assessment of mandibular condyle morphology using both MRI and clinical examination as the gold standard. *Oral Surg Oral Med Oral Pathol Oral Radiol Endod.* 2006 Aug;102(2):220–4.

Schropp L, Stavropoulos A, Gotfredsen E, Wenzel A. Comparison of panoramic and conventional cross-sectional tomography for preoperative selection of implant size. *Clin Oral Implants Res.* 2011 Apr;22(4):424–9.

Schwendicke F, Tzschoppe M, Paris S. Radiographic caries detection: A systematic review and meta-analysis. *J Dent.* 2015 Aug;43(8):924–33.

Senel B, Kamburoglu K, Uçok O, Yüksel SP, Ozen T, Avsever H. Diagnostic accuracy of different imaging modalities in detection of proximal caries. *Dentomaxillofac Radiol.* 2010 Dec;39(8):501–11.

Shahbazian M, Vandewoude C, Wyatt J, Jacobs R. Comparative assessment of panoramic radiography and CBCT imaging for radiodiagnostics in the posterior maxilla. *Clin Oral Investig.* 2014 Jan;18(1):293–300.

Sharan A, Madjar D. Correlation between maxillary sinus floor topography and related root position of posterior teeth using panoramic and cross-sectional computed tomography imaging. *Oral Surg Oral Med Oral Pathol Oral Radiol Endod.* 2006 Sep;102(3):375–81.

Special Committee to Revise the Joint AAE/AAOMR Position Statement on use of CBCT in Endodontics. AAE and AAOMR Joint Position Statement: Use of Cone Beam Computed Tomography in Endodontics 2015 Update. *Oral Surg Oral Med Oral Pathol Oral Radiol.* 2015 Oct;120(4):508–12.

Strauss RA, Wang N. Cone beam computed tomography and obstructive sleep apnoea. *Aust Dent J.* 2012;57:61–71.

Suomalainen A, Vehmas T, Kortensniemi M, Robinson S, Peltola J. Accuracy of linear measurements using dental cone beam and conventional multislice computed tomography. *Dentomaxillofac Radiol.* 2008 Jan;37(1):10–7.

Suphanantachat S, Tantikul K, Tamsailom S, Kosalagood P, Nisapakultorn K, Tavedhikul K. Comparison of clinical values between cone beam computed tomography and conventional intraoral radiography in periodontal and infrabony defect assessment. *Dentomaxillofac Radiol.* 2017 Aug;46(6):20160461.

Swennen GRJ, Schutyser F. Three-dimensional cephalometry: spiral multi-slice vs cone-beam computed tomography. *Am J Orthod Dentofacial Orthop.* 2006 Sep;130(3):410–6.

Tantanapornkul W, Mavin D, Prapaiphittayakun J, Phipatboonyarat N, Julphantong W. Accuracy of Panoramic Radiograph in Assessment of the Relationship Between Mandibular Canal and Impacted Third Molars. *Open Dent J.* 2016 Jun 23;10:322–9.

Terry GL, Noujeim M, Langlais RP, Moore WS, Prihoda TJ. A clinical comparison of extraoral panoramic and intraoral radiographic modalities for detecting proximal caries and visualizing open posterior interproximal contacts. *Dentomaxillofac Radiol.* 2016 Feb 12;45(4):20150159.

The Royal College of Radiologists. Effect of display type, DICOM calibration and room illuminance in bitewing radiographs Second Edition [Internet]. 2012 [cited 2017 Oct 8]. Available from:

[https://www.rcr.ac.uk/sites/default/files/docs/radiology/pdf/B_FCR\(12\)16_PACS_DDD.pdf](https://www.rcr.ac.uk/sites/default/files/docs/radiology/pdf/B_FCR(12)16_PACS_DDD.pdf)

- Thunthy KH, Yeadon WR, Nasr HF. An illustrative study of the role of tomograms for the placement of dental implants. *J Oral Implantol.* 2003;29(2):91–5.
- Tsuchida R, Araki K, Okano T. Evaluation of a limited cone-beam volumetric imaging system: comparison with film radiography in detecting incipient proximal caries. *Oral Surg Oral Med Oral Pathol Oral Radiol Endod.* 2007 Sep;104(3):412–6.
- Tyndall DA, Kohltfarber H. Application of cone beam volumetric tomography in endodontics. *Aust Dent J.* 2012 Mar;57 Suppl 1:72–81.
- Tyndall DA, Price JB, Tetradis S, Ganz SD, Hildebolt C, Scarfe WC, et al. Position statement of the American Academy of Oral and Maxillofacial Radiology on selection criteria for the use of radiology in dental implantology with emphasis on cone beam computed tomography. *Oral Surg Oral Med Oral Pathol Oral Radiol.* 2012;113(6):817–26.
- Tyndall DA, Rathore S. Cone-beam CT diagnostic applications: caries, periodontal bone assessment, and endodontic applications. *Dent Clin North Am.* 2008 Oct;52(4):825–41, vii.
- Udupa H, Mah P, Dove SB, McDavid WD. Evaluation of image quality parameters of representative intraoral digital radiographic systems. *Oral Surg Oral Med Oral Pathol Oral Radiol.* 2013 Dec;116(6):774–83.
- Vandenberghe B, Jacobs R, Bosmans H. Modern dental imaging: a review of the current technology and clinical applications in dental practice. *Eur Radiol.* 2010;20(11):2637–55.
- Vandenberghe B, Jacobs R, Yang J. Detection of periodontal bone loss using digital intraoral and cone beam computed tomography images: an in vitro assessment of bony and/or infrabony defects. *Dentomaxillofac Radiology.* 2008;37(5):252–60.
- Vazquez L, Al Din YN, Belser UC, Combesure C, Bernard J-P. Reliability of the vertical magnification factor on panoramic radiographs: clinical implications for posterior mandibular implants. *Clin Oral Implants Res.* 2011;22(12):1420–5.
- Vazquez L, Nizamaldin Y, Combesure C, Nedir R, Bischof M, Dohan Ehrenfest DM, et al. Accuracy of vertical height measurements on direct digital panoramic radiographs using posterior mandibular implants and metal balls as reference objects. *Dentomaxillofac Radiol.* 2013;42(2):20110429.
- Vazquez L, Saulacic N, Belser U, Bernard J-P. Efficacy of panoramic radiographs in the preoperative planning of posterior mandibular implants: a prospective clinical study of 1527 consecutively treated patients. *Clin Oral Implants Res.* 2008 Jan;19(1):81–5.
- Versteeg CH, Sanderink GC, van Ginkel FC, van der Stelt PF. An evaluation of periapical radiography with a charge-coupled device. *Dentomaxillofac Radiol.* 1998 Mar;27(2):97–101.
- Walker L, Enciso R, Mah J. Three-dimensional localization of maxillary canines with cone-beam computed tomography. *Am J Orthod Dentofacial Orthop.* 2005;128(4):418–23.
- Walter C, Schmidt JC, Dula K, Sculean A. Cone beam computed tomography (CBCT) for diagnosis and treatment planning in periodontology: A systematic review. *Quintessence Int.* 2016 Jan;47(1):25–37.
- Walter C, Weiger R, Dietrich T, Lang NP, Zitzmann NU. Does three-dimensional imaging offer a financial benefit for treating maxillary molars with furcation involvement? - A pilot clinical case series. *Clin Oral Implants Res.* 2011;23(3):351–8.
- Walter C, Weiger R, Zitzmann NU. Accuracy of three-dimensional imaging in assessing maxillary molar furcation involvement. *J Clin Periodontol.* 2010 May;37(5):436–41.
- Warner BF, Luna MA, Robert Newland T. Temporomandibular joint neoplasms and pseudotumors. *Adv Anat Pathol.* 2000 Nov;7(6):365–81.
- Watanabe H, Honda E, Tetsumura A, Kurabayashi T. A comparative study for spatial resolution and subjective image characteristics of a multi-slice CT and a cone-beam CT for dental use. *Eur J Radiol.* 2011 Mar;77(3):397–402.
- Wenzel A, Møystad A. Experience of Norwegian general dental practitioners with solid state and storage phosphor detectors. *Dentomaxillofac Radiol.* 2001 Jul;30(4):203–8.
- Wenzel A, Møystad A. Work flow with digital intraoral radiography: a systematic review. *Acta Odontol Scand.* 2010 Mar;68(2):106–14.
- Wenzel A. It is not Clear Whether Commonly used Radiographic Markers in Panoramic Images Possess Predictive Ability for Determining the Relationship between the Inferior Alveolar Nerve and the Mandibular Third Molar. *J Evid Based Dent Pract.* 2010;10(4):232–4.
- Wenzel A. Radiographic display of carious lesions and cavitation in approximal surfaces: Advantages and drawbacks of conventional and advanced modalities. *Acta Odontol Scand.* 2014 May;72(4):251–64.
- White SC, Heslop EW, Hollender LG, Mosier KM, Ruprecht A, ShROUT MK, et al. Parameters of radiologic care: An official report of the American Academy of Oral and Maxillofacial Radiology. *Oral Surg Oral Med Oral Pathol Oral Radiol Endod.* 2001 May;91(5):498–511.

White SC, Mallya SM. Update on the biological effects of ionizing radiation, relative dose factors and radiation hygiene. *Aust Dent J*. 2012 Mar;57 Suppl 1:2–8.

White SC, Pharoah MJ, Frcd C. The Evolution and Application of Dental Maxillofacial Imaging Modalities. 2008;52:689–705.

White SC, Pharoah MJ. *Oral Radiology: Principles and Interpretation*. Elsevier Health Sciences;2014. 679 p; 696p.

White SC, Pharoah MJ. The evolution and application of dental maxillofacial imaging modalities. *Dent Clin North Am*. 2008 Oct;52(4):689–705, v.

Winand C, Shetty A, Senior A, Ganatra S, De Luca Canto G, Alsufyani N, et al. Digital Imaging Capability for Caries Detection. *JDR Clinical & Translational Research*. 2016;1(2):112–21.

Witcher TP, Brand S, Gwilliam JR, McDonald F. Assessment of the anterior maxilla in orthodontic patients using upper anterior occlusal radiographs and dental panoramic tomography: a comparison. *Oral Surg Oral Med Oral Pathol Oral Radiol Endod*. 2010 May;109(5):765–74.

Wolff C, Mücke T, Wagenpfeil S, Kanatas A, Bissinger O, Deppe H. Do CBCT scans alter surgical treatment plans? Comparison of preoperative surgical diagnosis using panoramic versus cone-beam CT images. *J Craniomaxillofac Surg*. 2016 Oct;44(10):1700–5.

Wriedt S, Jaklin J, Al-Nawas B, Wehrbein H. Impacted upper canines: examination and treatment proposal based on 3D versus 2D diagnosis. *J Orofac Orthop*. 2012 Jan;73(1):28–40.
Yepes JF, Al-Sabbagh M. Use of cone-beam computed tomography in early detection of implant failure. *Dent Clin North Am*. 2015 Jan;59(1):41–56.